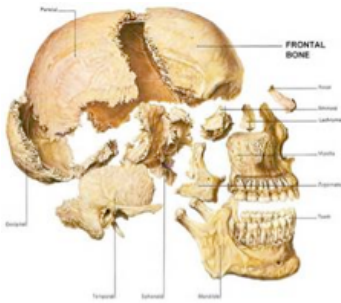


THE ANATOMY OF THE FACIAL BONES

Review this PDF paying special attention to the bolded references. Refer to the Anatomy Coloring Book pages listed below and color in the bolded bones. If you have an older or revised edition the page numbers may be different.



We begin our exploration at the front of the skull where we find the **facial bones** (all on pg. 22 & 23). Move your fingers to the top part of the nose where it meets the face. Walk and wiggle your finger out toward the tip of your nose until you feel the end of the **nasal bone**. Walk out to the very end of your nose and know that deep inside your nose lies a bone called the **vomer**. We also find here the **inferior nasal concha**. Bring your fingers back up your nose and just into the eye socket on either side of your nose and you'll find the **lacrima**. Bring the fingers a little deeper and down toward the bottom of the eye socket and you'll find a facial bone called the **palatine**.

Walk your fingers out to your cheeks and feel the **zygomatic**. Walk your fingers toward your nose until you fall into the hollow space between the nose and your cheek. Continue walking the fingers to the space between the nose and top lip. This is the space of the **maxilla**.

Bring your fingers onto the jaw and move the jaw up and down this is the **mandible** (pg. 22).